



## Brief Communication

# Recurrent pulmonary embolism in a 13-year-old male homozygous for the prothrombin G20210A mutation combined with protein S deficiency and increased lipoprotein (a)

Andrea Kosch<sup>a,\*</sup>, Ralf Junker<sup>b,c</sup>, Cornelia Wermes<sup>d</sup>, Ulrike Nowak-Göttl<sup>a</sup><sup>a</sup>Department of Pediatric Hematology and Oncology, Westfälische Wilhelms-Universität Münster, Albert Schweitzer-Str. 33, D-48149 Münster, Germany<sup>b</sup>Department of Clinical Chemistry and Laboratory Medicine, University of Münster, Münster, Germany<sup>c</sup>Department of Arteriosclerosis Research, University of Münster, Münster, Germany<sup>d</sup>Department of Internal Medicine, Medical School of Hanover, Hanover, Germany

Received 16 August 2001; received in revised form 12 November 2001; accepted 12 November 2001

Accepting Editor: W. Muntean

## Abstract

We report the case of a 13-year-old male presenting with recurrent symptoms of respiratory distress after a trauma of the lower limb. Pulmonary symptoms had been misinterpreted for several weeks and only marked symptoms of deep venous (DVT) and caval vein thrombosis later prompted the correct diagnosis of DVT and embolic events and subsequently a successful thrombolytic therapy. The case reported here shows a diagnostic pitfall of pulmonary embolism in an adolescent. It emphasizes the need to consider the possibility of thromboembolic events also in young children and adolescents presenting with atypical pulmonary symptoms and suffering from pulmonary diseases not responding to antibiotic therapy. In addition, although the homozygous PT A20210A gene mutation is a rare defect and its relevance as a risk factor on its own remains to be elucidated, this case suggests that a complete thrombophilia laboratory workup should be performed in young patients with a first symptomatic thromboembolic onset. © 2002 Elsevier Science Ltd. All rights reserved.

**Keywords:** Homozygous prothrombin A20210A mutation; Protein S deficiency; Lipoprotein (a); Deep venous thrombosis; Pulmonary embolism

## 1. Introduction

Pulmonary embolism is a serious complication of deep venous thrombosis (DVT) but is rare in pediatric patients. Although pulmonary emboli can be detected by scintigraphy or angiography in up to 50% of adult patients with DVT, diagnosis of this vascular accident may be difficult in young patients, and inadequate therapy for pneumonia or other chest-related diseases is common [1].

Several prothrombotic genetic risk factors are known to predispose to thrombotic events with manifestation at young age. The heterozygous mutation of the G20210G prothrombin (PT) gene has recently been suggested as a prothrombotic risk factor [2]. However, the clinical significance of the

homozygous prothrombotic variant for the risk of thrombosis is not clear, and reports are sparse and equivocal [3,4].

We report the case of a pediatric patient with the homozygous A20210A PT mutation suffering from deep venous thrombosis with recurrent symptomatic pulmonary embolism. Therapy for pneumonia had been initiated after onset of clinical symptoms and the correct diagnosis was made several months later. Laboratory screening for prothrombotic risk factors revealed a homozygous carrier state for the PT G20210A mutation, as well as protein S deficiency and an elevated level of lipoprotein (a).

## 2. Laboratory methods

### 2.1. Blood samples

With informed parental consent, blood samples were collected 3 months after the acute thrombotic onset by

*Abbreviations:* ACA, anticardiolipin antibodies; DVT, deep vein thrombosis; Hey, Moderate hyperhomocystenemia; PE, pulmonary embolism; MI, myocardial infarction; TIA, transient ischemic attack

\* Corresponding author. Tel.: +49-251-8347702; fax: +49-251-8347828.

E-mail address: koscha@uni-muenster.de (A. Kosch).

peripheral venipuncture, and measurement of plasma and coagulation parameters as well as DNA analysis were performed as recently described [5].

## 2.2. Assays for genotyping

The factor V (FV) G1691A and the PT G20210A genotypes were determined by polymerase chain reaction and analysis of restriction fragments as previously reported [2,6,7].

## 2.3. Assays for plasma proteins

Amidolytic protein C and antithrombin activities were measured on an ACL 300 analyzer (Instrumentation Laboratory, Germany) using chromogenic substrates (Chromogenix, Sweden). Free protein S antigen, total protein S, and protein C antigen were measured using commercially available ELISA assay kits (Stago, France). Lp(a) and anticardiolipin antibodies (IgM and IgG) were determined with ELISA techniques (Chromogenix).

Criteria for the hereditary nature of a hemostatic defect were its presence in at least one further first or second degree family member and/or the identification of a causative gene mutation [5,8].

## 3. Case

A 13-year-old male presented with recurrent symptoms of respiratory distress. The patient's history revealed no

abnormalities until 4 months prior to admission when the patient suffered a trauma of the ankle with immobilization for several days. Following that episode, the patient developed unspecific pulmonary symptoms that were interpreted as "longstanding bronchitis." Later on pleuritis was suspected, but symptoms persisted despite antibiotic therapy. Three weeks later, respiratory symptoms were accompanied by recurrent abdominal pain and an appendectomy was performed without heparin prophylaxis. However, surgical exploration and histological analysis revealed no inflammatory changes in the appendix.

Although the postsurgical course was complicated by weight loss, fever, and persistent cough, the patient was discharged 3 weeks after the appendectomy. Weight loss, coughing, and subfebrile temperatures continued at home. Painful swelling of both legs finally led to the suspected diagnosis of recurrent deep venous thrombosis and pulmonary embolism. Moreover, the mother's family history (cousin: Fig. 1) was positive for recurrent venous thromboembolism due to a known familial protein S type I deficiency.

The 13-year-old patient was immediately admitted to hospital, where phlebography and compression Doppler sonography revealed a fresh thrombus in the left popliteal vein, and a lung scan confirmed multiple older and fresh pulmonary embolisms. Moreover, an inferior caval vein thrombosis was suspected by Doppler sonography but was not clearly verified by venography. In addition, a post-thrombotic syndrome in both legs was documented radiographically. Thrombolytic therapy with urokinase and concomitant heparin was performed for 8 days, followed by resolution of the pulmonary symptoms. Moreover, the

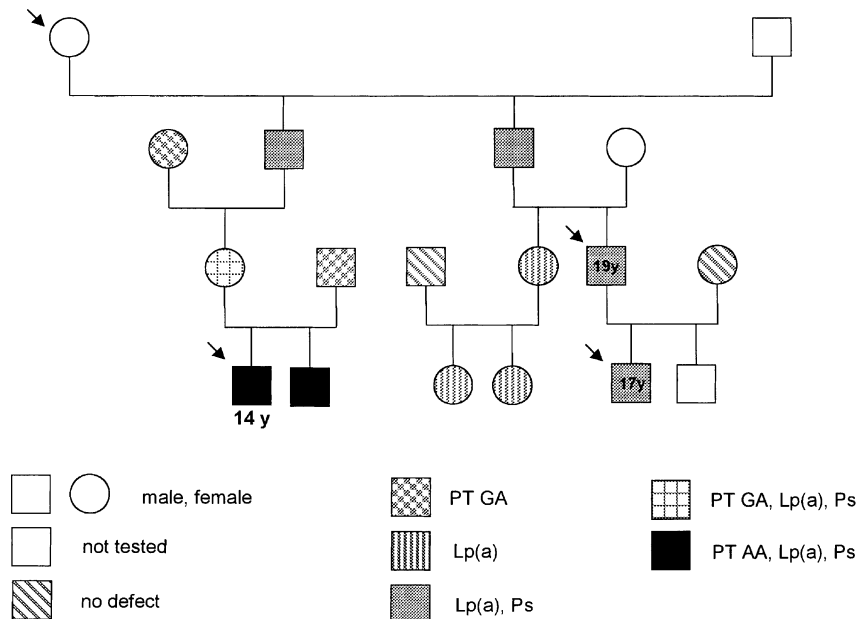


Fig. 1. Pedigree of a thrombosis-prone family suffering from the PT G20210A gene mutation, protein S type I deficiency, and increased Lp (a). The arrows indicate symptomatic family members.

Table 1

Symptomatic carriers of the homozygous PT A20210A mutation (first event: median/range age 34/13–66 years)

Author	Further genetic prothrombotic defects	Triggering factors	Location of thrombosis	Age at first thrombotic event	Gender
Howard et al. [14]	FV G1691A	Nicotine abuse, physical exercise	Iliac veins, PE, MI	24	Male
Scott et al. [18]	–	Pregnancy	DVT	18	Female
Kapur et al. [19]	Hcy	–	Retinal veins	66	Male
Gonzalez Ordonez et al. [16]	–	Surgery	DVT/pelvic veins, TIA	63	Male
Halbmayer et al. [21]	FV G1691A	Infection	Venous thromboembolism	23	Male
	FV G1691A	Surgery	PE	26	Female
Kyrle et al. [22]	–	Pregnancy	Superficial veins	<35	Female
	–	–	DVT	40	Male
Morange et al. [13]	–	–	DVT, PE	44	Male
Zawadzki et al. [23]	–	–	DVT, PE, mesenteric veins	40	Male
	–	–	PE	30	Female
Kling et al. [17]	–	T-cell lymphoma	Retinal artery/veins	44	Male
Eikelboom et al. [20]	–	Surgery	DVT	66	Female
Corral et al. [15]	FV G1691A	Pregnancy	DVT	34	Female
	FV G1691A	Trauma	DVT, PE	39	Male
	FV G1691A	Surgery	DVT	41	Female
Giordano et al. [24]	ACA	–	Superficial veins	26	Female
Mainardi et al. [25]	FV A1691A	–	DVT	34	Male
Wulf et al. [26]	FV A1691A	–	Superficial veins	18	Male
Acquila et al. [27]	–	Pregnancy	DVT	22	Female
Our case	Protein S deficiency, Lp(a)	Trauma	DVT, pelvic veins, PE	13	Male

ACA: anticardiolipin antibodies; DVT: deep vein thrombosis; Hcy: moderate hyperhomocystenemia; PE: pulmonary embolism; MI: myocardial infarction; TIA: transient ischemic attack.

swelling of the legs was reduced. Subsequently, the patient was treated with enoxaparin (1.5 mg/kg/d). Laboratory analysis beyond the acute phase (3 and 6 months, respectively) revealed normal values for aPTT, PT, fibrinogen, antithrombin, and protein C. Free protein S antigen concentrations were repeatedly between 24% and 32% (3 and 6 months after diagnosis of PE), and Lp(a) was clearly increased at 80 mg/dl (normal <30 mg/dl).

In addition, genetic analysis revealed a homozygous state for the PT G20210A mutation. FV G1691A showed the normal GG genotype. Laboratory screening of the family revealed that both parents were heterozygous carriers of the PT variant. The asymptomatic mother carried additional protein S deficiency type I (39% of normal) and showed increased Lp(a) at 76 mg/dl. In the 19-year-old healthy brother the same prothrombotic risk profile as in the patient was present; however, he did not show signs of vascular accidents until today. The father, however, had developed coronary artery disease at the age of 49. In the mother's family the cousin and his son, both showing protein S deficiency type I along with increased Lp(a), had suffered recurrent deep venous thrombosis at an age of 17 and 19 years, respectively (Fig. 1).

Because of the severe and early thrombotic onset (deep venous thrombosis, suspected caval venous occlusion, and pulmonary embolism) associated with a genetic recombination of at least three important prothrombotic risk factors and the mother's positive family history, anticoagulant therapy with vitamin K antagonists was started. Two years after initiation of the therapy the

patient is still in good clinical condition and has suffered no further complications.

#### 4. Discussion

The case presented here reports on a 13-year-old male suffering from recurrent pulmonary embolism following deep venous thrombosis after a simple football trauma. As underlying genetic risk factors, the homozygous PT A20210A mutation, protein S type I deficiency, and increased Lp(a) were diagnosed. On the one hand, this case is of interest because the diagnosis was delayed and inappropriate treatment for pneumonia had been initiated despite a family history of thrombosis being well documented. It also illustrates that the rare event of pulmonary embolism can be overlooked in childhood patients.

On the other hand, the genetic profile predisposing the patient to thromboembolism is of interest: The PT G20210A mutation in its heterozygous form has been recently proposed as a prothrombotic risk factor for venous thrombosis in Caucasian populations [2,9,10]. Ethnic and geographic differences ranging from a prevalence rate of 0% to 4% in populations not affected by thrombotic events have been reported for this defect [11]. As in adult patients, the heterozygous form of this PT variant has been suggested as a prothrombotic risk factor in Caucasian pediatric patients with venous thromboembolism [5,12]. Nevertheless, the significance of the rare homozygous mutation alone as a prothrombotic risk factor has been questioned by reports of

various homozygous subjects with (Table 1) [13–27]] and without manifest thrombosis [3,13,20,21,26,28–31].

The case reported here is the youngest symptomatic individual in a large thrombosis-prone family and the youngest patient with a thromboembolic event reported so far to be carrying the homozygous PT mutation. This suggests, however, that the homozygous PT A20210A mutation increases the prothrombotic risk in patients carrying further prothrombotic risk factors, such as the heterozygous FV G1691A mutation, protein S deficiency, or increased Lp(a). However, the significance of the homozygous PT A20210A mutation as an isolated risk cannot be concluded from our case, since in this patient the PT mutation was combined with other established prothrombotic risk factors, especially with a protein S type I deficiency. The importance of the isolated homozygous PT A20210A mutation remains to be clarified by further family studies.

## References

- [1] Meignan M, Rosso J, Gauthier H, Brunengo F, Claudel S, Sagnard L, d'Azemar Simonneau G, Charbonnier B. Systematic lung scans reveal a high frequency of silent pulmonary embolism in patients with proximal deep venous thrombosis. *Arch Intern Med* 2000; 160(2):159–64.
- [2] Poort SR, Rosendaal FR, Reitsma PH, Bertina R. A common genetic variation in the 3'-untranslated region of the prothrombin gene is associated with elevated plasma prothrombin levels and an increase in venous thrombosis. *Blood* 1996;88(10):3698–703.
- [3] Girolami A, Simioni P, Tormene D, Scarano L. Two additional homozygous patients for the 20210 prothrombin polymorphism with no venous thrombosis (Letter). *Thromb Res* 1999;96(5):415–7.
- [4] Tosetto A, Missiaglia E, Frezzato M, Rodeghiero F. The VITA project: prothrombin G20210A mutation and venous thromboembolism in the general population. *Thromb Haemostasis* 1999;82(5): 1395–8.
- [5] Junker R, Koch HG, Auberger K, Münchow N, Ehrenforth S, Nowak-Göttl U. Prothrombin G20210A gene mutation and further prothrombotic risk factors in childhood thrombophilia. *Arterioscler, Thromb, Vasc Biol* 1999;19(10):2568–72.
- [6] Bertina RM, Koeleman BP, Koster T, Rosendaal FR, Dirven RJ, de Ronde H, van Velden PA, Reitsma PH. Mutation in blood coagulation factor V associated with resistance to activated protein C. *Nature* 1994;369(6475):64–7.
- [7] Frosst P, Blom HJ, Milos R, Goyette P, Sheppard CA, Matthews RG, Boers GJ, den Heijer M, Kluijtmans LA, van den Heuvel LP. A candidate genetic risk factor for vascular disease: a common mutation in methylenetetrahydrofolate reductase. *Nat Genet* 1995;10(1):111–3.
- [8] Nowak-Göttl U, Junker R, Hartmeier M, Koch HG, Münchow N, Assmann G, von Eckardstein A. Increased lipoprotein (a) is an important risk factor for venous thrombosis in childhood. *Circulation* 1999;100(7):743–8.
- [9] Arruda VR, Annichino-Bizzacchi JM, Goncalves MS, Costa FF. Prevalence of the prothrombin gene variant (nt20210A) in venous thrombosis and arterial disease. *Thromb Haemostasis* 1997;78(6):1430–3.
- [10] Makris M, Preston FE, Beauchamp NJ, Cooper PC, Daly ME, Hampton KK, Bayliss P, Peake IR, Miller GJ. Co-inheritance of the 20210A allele of the prothrombin gene increases the risk of thrombosis in subjects with familial thrombophilia. *Thromb Haemostasis* 1997;78(6):1426–9.
- [11] Rosendaal FR, Doggen CJ, Zivelin A, Arruda VR, Aiach M, Siscovick DS, Hillarp A, Watzke HH, Bernardi F, Cumming AM, Preston FE, Reitsma PH. Geographic distribution of the 20210 G to A prothrombin variant. *Thromb Haemostasis* 1998; 79(4):706–8.
- [12] Junker R, Nowak-Göttl U. The prothrombin G20210A mutation—a common cause of thrombophilia? *J Lab Med* 2000;22:472–82.
- [13] Morange PE, Barthelet MC, Henry M, Fontanet H, Aillaud MF, Alessi MC, Juhan-Vague I. A three-generation family presenting five cases of homozygosity for the 20210 G to A prothrombin variant (Letter). *Thromb Haemostasis* 1998;80(5):859–60.
- [14] Howard TE, Marusa M, Channell C, Duncan A. A patient homozygous for a mutation in the prothrombin gene 3'-untranslated region associated with massive thrombosis. *Blood Coagulation Fibrinolysis* 1997;8(5):316–9.
- [15] Corral J, Zuazu-Jausoro I, Rivera J, Gonzalez-Conejero R, Ferrer F, Vicente V. Clinical and analytical relevance of the combination of prothrombin 20210 A/A and factor V Leiden: results from a large family. *Br J Haematol* 1999;105(2):560–3.
- [16] Gonzalez Ordóñez AJ, Medina Rodríguez JM, Fernandez Alvarez CR, Macias Robles MD, Coto Garcia E. A patient homozygous for mutation 20210A in the prothrombin gene with venous thrombosis and transient ischemic attacks of thrombotic origin. *Haematologica* 1998; 83(11):1050–1.
- [17] Kling F, Macarez R, Robinet A, Kouassi FX, Colin J. Mixed retinal thrombosis in a patient carrying prothrombin gene mutation in a homozygote state. *J Fr Ophthalmol* 1999;22(9):979–81.
- [18] Scott CM, Hanley JP, Ludlam CA, Stirling D. Homozygosity for a factor II polymorphism associated with thrombosis during pregnancy. *Thromb Haemostasis* 1997;770 (Suppl., Abstract).
- [19] Kapur RK, Mills LA, Spitzer SG, Hultin MB. A prothrombin gene mutation is significantly associated with venous thrombosis. *Arterioscler, Thromb, Vasc Biol* 1997;17(11):2875–9.
- [20] Eikelboom JW, Ivey L, Ivey J, Baker RI. Familial thrombophilia and the prothrombin 20210A mutation: association with increased thrombin generation and unusual thrombosis. *Blood Coagulation Fibrinolysis* 1999;10(1):1–5.
- [21] Halbmayer WM, Kahls T, Haushofer A, Breier F, Fischer M. Venous thromboembolism at a young age in a brother and sister with coinheritance of homozygous 20210 A/A prothrombin mutation and heterozygous 1691G/A factor V Leiden mutation. *Blood Coagulation Fibrinolysis* 1999;10(5):297–302.
- [22] Kyrle PA, Mannhalter C, Beguin S, Stumpflen A, Hirschl M, Weltermann A, Stain M, Brenner B, Speiser W, Pabinger I, Lechner K, Eichinger S. Clinical studies and thrombin generation in patients homozygous or heterozygous for the G20210A mutation in the prothrombin gene. *Arterioscler, Thromb, Vasc Biol* 1998;18(8):1287–91.
- [23] Zawadzki C, Gaveriaux V, Trillot N, Bel A, Alhenc-Gelas M, Preudhomme C, Jude B. Homozygous G20210A transition in the prothrombin gene associated with severe venous thrombotic disease: two cases in a French family (Letter) *Thromb Haemostasis* 1998;80(6):1027–8.
- [24] Giordano P, Lucia D, Coppola B, Iolascon A. Homozygous prothrombin gene mutation and ischemic cerebrovascular disease: a case report. *Acta Haematol* 1999;102(2):101–3.
- [25] Mainardi JR, Pelsma PM, Koning H, van der Meer J, Middeldorp S, Buller HR, Hamulyak K. Double-homozygosity for factor V Leiden and the prothrombin gene G20210A variant in a young patient with idiopathic venous thrombosis (Letter). *Blood* 1999;94(5): 1828–9.
- [26] Wulf GM, van Deerlin VM, Leonard DG, Bauer KA. Thrombosis in a patient with combined homozygosity for the factor V Leiden mutation and a mutation in the 3'-untranslated region of the prothrombin gene. *Blood Coagulation Fibrinolysis* 1999;10(2):107–10.

- [27] Acquila M, Biocchi MP, Mori PG, Odino S, Valetto A, Bottini F. A homozygosity state for 20210A prothrombin variant in a young woman as cause of a deep venous thrombosis during pregnancy (Letter). *Eur J Haematol* 2000;65(1):80–1.
- [28] Simioni P, Tormene D, Manfrin D, Gavasso S, Luni S, Stocco D, Girolami A. Prothrombin antigen levels in symptomatic and asymptomatic carriers of the 20210A prothrombin variant. *Br J Haematol* 1998;103(4):1045–50.
- [29] Souto JC, Mateo J, Soria JM, Llobet D, Coll I, Borrell M, Fontcuberta J. Homozygotes for prothrombin gene 20210A allele in a thrombophilic family without clinical manifestations of venous thromboembolism. *Haematologica* 1999;84(7):627–32.
- [30] Akar N, Egin Y. A further case of homozygous G20210A prothrombin gene mutation without thromboembolic events. *Clin Appl Thromb Hemostasis* 1999;5(4):284.
- [31] Alatri A, Franchi F, Moia M. Homozygous G20210A prothrombin gene mutation without thromboembolic events: a case report (Letter). *Thromb Haemostasis* 1998;80(6):1028–9.